# High-resolution CT phenotypes in pulmonary sarcoidosis: a multinational Delphi consensus study

*Sujal R Desai, Nishanth Sivarasan, Kerri A Johannson, Peter M George, Daniel A Culver, Anand Devaraj, David A Lynch, David Milne, Elisabetta Renzoni, Hilario Nunes, Nicola Sverzellati, Paolo Spagnolo, Robert P Baughman, Ruchi Yadav, Sara Piciucchi, Simon L F Walsh, Vasileios Kouranos, Athol U Wells, and the Sarcoid Delphi Group**

**One view of sarcoidosis is that the term covers many different diseases. However, no classification framework exists for the future exploration of pathogenetic pathways, genetic or trigger predilections, patterns of lung function impairment, or treatment separations, or for the development of diagnostic algorithms or relevant outcome measures. We aimed to establish agreement on high-resolution CT (HRCT) phenotypic separations in sarcoidosis to anchor future CT research through a multinational two-round Delphi consensus process. Delphi participants included members of the Fleischner Society and the World Association of Sarcoidosis and other Granulomatous Disorders, as well as members' nominees. 146 individuals (98 chest physicians, 48 thoracic radiologists) from 28 countries took part, 144 of whom completed both Delphi rounds. After rating of 35 Delphi statements on a five-point Likert scale, consensus was achieved for 22 (63%) statements. There was 97% agreement on the existence of distinct HRCT phenotypes, with seven HRCT phenotypes that were categorised by participants as non-fibrotic or likely to be fibrotic. The international consensus reached in this Delphi exercise justifies the formulation of a CT classification as a basis for the possible definition of separate diseases. Further refinement of phenotypes with rapidly achievable CT studies is now needed to underpin the development of a formal classification of sarcoidosis.**

*Lancet Respir Med* 2024; 12: 409–18

Published Online December 14, 2023 https://doi.org/10.1016/S2213-2600(23)00267-9

*Study group members listed in the appendix (pp 2–6)

**Department of Radiology** (Prof S R Desai MD, N Sivarasan MD, Prof A Devaraj MD) **and Interstitial Lung Disease Unit** (P M George PhD, E Renzoni PhD, V Kouranos PhD, Prof A U Wells MD), **Royal Brompton Hospital, London, UK; National Heart and Lung Institute** (Prof S R Desai, P M George, Prof A Devaraj, E Renzoni, S L F Walsh PhD, V Kouranos, Prof A U Wells) **and Margaret Turner Warwick Centre for Fibrosing Lung Disease** (Prof S R Desai, P M George, Prof A Devaraj, E Renzoni, V Kouranos, Prof A U Wells), **Imperial College London, London, UK; Department of Medicine, University of Calgary, Calgary, AB, Canada** (Prof K A Johannson MD); **Department of Pulmonary Medicine** (D A Culver DO) **and Imaging Institute** (R Yadav MD), **Cleveland Clinic, Cleveland, OH, USA; Department of Radiology, National Jewish Health, Denver, CO, USA** (Prof D A Lynch MBBCh); **Department of Radiology, Auckland City Hospital, Auckland, New Zealand** (D Milne FRANZCR); **Service de Pneumologie, Hôpital Avicenne, Université Sorbonne Paris Nord, Paris, France** (Prof H Nunes MD); **Section of Diagnostic Imaging, University of Parma, Parma, Italy** (Prof N Sverzellati PhD); **Section of Respiratory Diseases, University of Padova, Padova, Italy** (Prof P Spagnolo MD); **Department of Medicine, University of Cincinnati Medical Center, Cincinnati, OH, USA** (Prof R P Baughman MD); **Department of Radiology, GB Morgagni Hospital, Forlì, Italy** (S Piciucchi MD)

## Introduction

Sarcoidosis is often viewed as a single disease of unknown cause that is characterised by the presence of non-caseating granulomas in multiple organs. However, a prevalent alternative view is that sarcoidosis is an umbrella term that describes a number of separate diseases. The rationale for the latter view includes major variability in patterns of lung function impairment (including obstructive, restrictive, and mixed ventilatory defects), natural history, treatment course, and putative microbial triggers.[1–4] Biopsy data—the traditional means of distinguishing between entities in other interstitial lung diseases (ILDs)—have not been used to identify distinct pulmonary phenotypes in sarcoidosis. Histological evaluation relies mainly on sampling of lymph nodes or small bronchoscopic specimens. The current study was undertaken to explore the concept that in pulmonary sarcoidosis, evaluation based on CT findings might provide a more discriminatory morphological classification as a framework for future clinical research and pathogenetic studies.

The use of CT has several potential advantages. Although pattern recognition is common to both biopsy and CT, the latter allows evaluation of the whole lung parenchyma. In pulmonary sarcoidosis, it is well known that morphological manifestations are highly variable, to a degree that is rarely seen in other individual ILDs;[1–3,5,6] however, in stark contrast to CT, the grouping or staging of sarcoidosis on chest radiography, as proposed by Scadding,[7] does not allow fine morphological distinctions to be made. Against this background, to date, formal separation of morphological phenotypes based on CT appearances has not been attempted. The aim of the current study was to reach consensus on phenotypes in pulmonary sarcoidosis that are recognisable on high-resolution CT (HRCT) as a basis for the development of a morphological classification that will be applicable to future research centred on both pathogenetic pathways and clinical care.

## Methods

The study comprised the following two stages: development of statements, and a two-round online Delphi consensus process to rate the importance of the statements. The study was approved by the UK National Health Service Health Research Authority (Integrated Research Application System approval number 276717) and structured according to proposed methodological criteria for Delphi studies.[8]

### Study groups and participants

For the purposes of the current study, a central Delphi Study Management Committee (DSMC) was formed, comprising four members: two radiologists (SRD and NSi), a chest physician experienced in the management of ILD (AUW), and a second chest physician with specific expertise in the conduct of Delphi studies (KAJ).

In the first step, the DSMC invited a Core Expert Panel of 13 experts, from seven countries, to participate in the initial qualitative phase (figure 1) and 11 of 13 (85%) agreed to participate. Core Expert Panel members were chosen on the basis of the following: (1) an affiliation with and established practice in an international teaching institution; and (2) verifiable research contributions in sarcoidosis, ILDs, or both. The Core Expert Panel comprised chest physicians (n=5; DAC, ER, HN, PS, RPB) and thoracic radiologists (n=6; AD, DAL, DM, NSv, RY, and SP). The principal role of the Core Expert Panel was to participate in thematic interviews to facilitate the development of statements for the Delphi surveys (see below).

## Key messages

### Rationale and approach

- Despite the unifying presence of non-caseating granulomata, heterogeneity in lung function profiles, outcomes, treatment responses, and radiological appearances has led to the not unreasonable notion that sarcoidosis might simply be a convenient label for a group of different disorders
- With CT, in contrast to biopsy material, morphological abnormalities in the whole lung can be evaluated; however, the use of CT to stratify patients according to morphological differences has never been attempted
- As a prelude to the proposal of a new morphological classification of sarcoidosis, we sought to establish consensus on the principal or recognisable high-resolution CT (HRCT) phenotypes in sarcoidosis via a literature review and a two-round web-based Delphi process to rate 35 statements; 146 experts (pulmonary physicians and thoracic radiologists from 28 countries) were involved, with 144 participating in both Delphi rounds

### Findings

- There was final consensus for 22 of 35 statements (63%) presented across the two Delphi rounds; participants reached agreement on seven HRCT phenotypes broadly termed non-fibrotic (comprising micronodular or macronodular patterns and consolidation) or likely to be fibrotic (manifest as bronchocentric reticulation with or without dense parenchymal opacification—with or without cavitation or fibrobullous destruction—or large bronchocentric masses, mimicking progressive massive fibrosis)
- Overwhelming agreement (95%) was also reached on a statement—not previously emphasised in published sarcoidosis guidelines—that HRCT should be performed at baseline in patients with sarcoidosis and evidence of pulmonary interstitial involvement

### Future directions and implications

- This Delphi process sets the scene for future studies that should inform the development of a CT classification of sarcoidosis: first, variability between observers in the recognition of HRCT phenotypes must be tested; second, the prevalence of individual phenotypes in larger international cohorts needs to be established; third, the clinical and prognostic significance of patients not satisfying phenotypic criteria warrants evaluation; and, finally, research is needed to test whether (and, if so, how frequently) evolution from one morphological phenotype to another occurs in sarcoidosis
- Final agreement on HRCT phenotypes, based on the investigations highlighted above, will not only support the development of a new morphological classification, but also anchor further avenues of exploration, including disease behaviour, genetic profiles, and important pathogenetic mechanisms in sarcoidosis

Correspondence to: Prof Sujal R Desai, Department of Radiology, Royal Brompton Hospital, London SW3 6NP, UK
**s.desai@rbht.nhs.uk**

See Online for appendix

For the Delphi surveys, a system was devised to facilitate the recruitment of international experts that involved a Nominating Panel and nominees. Nominators were invited members of the Fleischner Society and the World Association of Sarcoidosis and other Granulomatous Disorders with proven expertise and a track-record of peer-reviewed publications in sarcoidosis, ILDs, or both. Members of the Nominating Panel were invited both to participate in the Delphi process and to nominate up to three nominees (physicians or radiologists) with experience in sarcoidosis; the invitation letter to Nominating Panel members stressed the importance of achieving geographical and gender representation among nominees. The final list of Delphi participants comprised members of (1) the Core Expert Panel, (2) the Nominating Panel, and (3) the nominees (with the Nominating Panel and their nominees comprising the Sarcoid Delphi Group; see appendix pp 2–6).

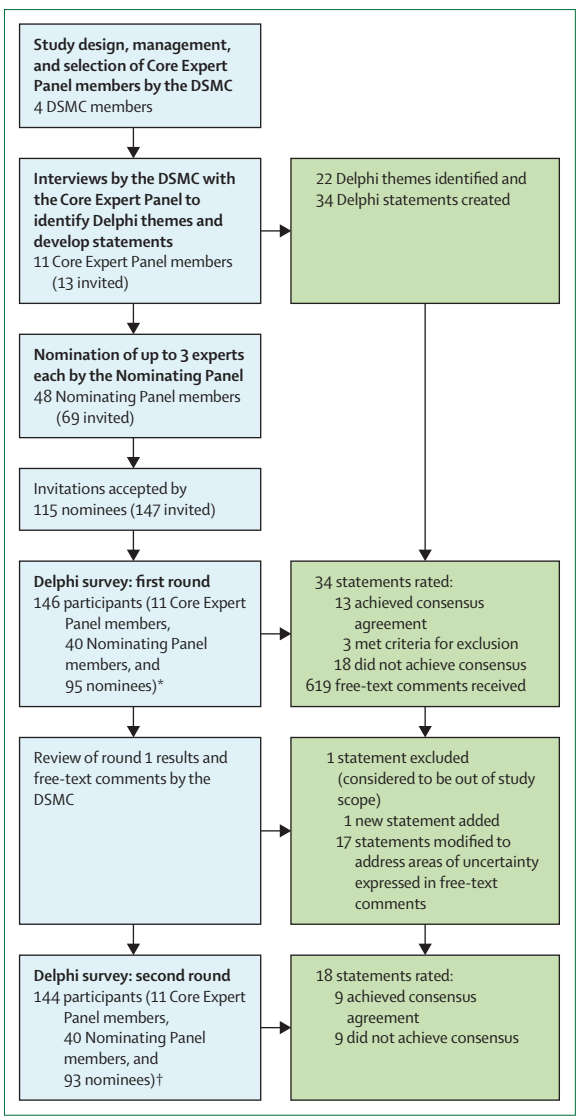


***Figure 1:*** **Overview of consensus development process and study participants**
The DSMC, which comprised four experts (SRD, NSi, KAJ, and AUW), convened the Core Expert Panel, conducted preliminary themed interviews, and oversaw the Delphi process. The Nominating Panel (ie, members of the Fleischner Society and the World Association of Sarcoidosis and other Granulomatous Disorders) participated in the Delphi process and nominated up to three experts in the field (nominees). Delphi participants comprised Core Expert Panel members, Nominating Panel members, and nominees. DSMC=Delphi Study Management Committee. *28 individuals who had originally accepted the invitations to participate did not complete the Delphi process. †Two individuals who had completed the first round of the Delphi process did not complete the second round.

## Literature review

A detailed PubMed literature search was performed to evaluate existing data on CT patterns and phenotypes. The MeSH terms "computed tomography, x-ray", "pulmonary sarcoidosis", and "imaging" were used to

identify studies published between Jan 1, 1980, and Jan 31, 2021. Titles were screened by NSi for case reports and observational studies published in English that evaluated CT appearance in pulmonary sarcoidosis. Review articles were also used to identify any further relevant studies. The data gathered from the literature search were used to contextualise, but not influence, the subsequent interview stage.

### Delphi statements and surveys

To develop the statements for the Delphi surveys, a member of the DSMC (NSi) conducted individual virtual interviews on Zoom with Core Expert Panel members using open-ended questions designed to encourage experts to provide opinions on broad discussion themes. The interviews covered five broad clinical–radiological–pathological themes: (1) recognition of distinct HRCT appearances in sarcoidosis from the experts' own clinical practice; (2) definition and categorisation of principal HRCT phenotypes; (3) clinical or prognostic implications of HRCT phenotypes (eg, response to treatment and survival); (4) possible relationships between HRCT phenotypes and lung function; and (5) potential relationships between HRCT phenotypes and broncho-alveolar lavage profiles. Interviews were continued until theme saturation was achieved (judged by the interviewer as recurring themes emerged).

Virtual meetings were recorded and transcribed using Rev, a commercial transcription service. Meeting transcripts were subsequently reviewed and condensed into key concepts by NSi using a content analysis approach.[9] Statements for the first round of the Delphi process were created by the DSMC using concepts or themes raised during interviews with the Core Expert Panel and based on the clinical and radiological experience of the DSMC (appendix p 7).

For the Delphi surveys, statements were presented to participants in English using Qualtrics, a commercial web-based survey tool that provides a user-interface for data collection (see appendix pp 8–9 for the full list of statements). The order of presentation of the statements was the same for all participants. For each Delphi statement, participants were required to indicate a level of agreement using a five-point Likert scale as follows: strongly agree, agree, neutral or unsure, disagree, or strongly disagree.[10] In the first Delphi round, participants were also encouraged to add free-text comments for each statement, including any proposed changes, clarifications, and potential new questions, which were assessed by the DSMC for inclusion in the subsequent round. For the majority of Delphi statements regarding HRCT appearances, anonymised full volumetric sample HRCT datasets were provided as visual examples. All participants were sent individualised links to the survey by email via the Qualtrics platform, with the request to complete the survey in 4 weeks or less, with weekly reminders from the DSMC.

Outlining the criteria for termination of a Delphi study is an important study quality metric.[8] Accordingly, from the outset, we defined the stopping criteria for the proposed Delphi study as termination after two rounds. The two rounds were composed as follows: a first round for the consideration of all initial Delphi statements; and a second round for the clarification of issues and questions raised in the first round (with provision of results from the first round where relevant), refinement of questions on the basis of participants' comments, and the addition of further Delphi statements, where relevant. A two-round method was judged to be appropriate to allow initial statements to be refined on the basis of results and participant feedback; additional rounds were considered unlikely to yield greater consensus and risked increasing participant attrition.[11] Furthermore, the clinical utility of any established phenotypes would require validation in formal research studies rather than being based on expert opinion.

### Statistical analysis

The definition of what constitutes consensus in a Delphi survey varies.[12] For the current study, an a priori threshold of 70% or more agreement (strongly agree or agree) was used to define consensus agreement on the basis that a large number of participants were to be included, which would probably result in an inherently lower standard deviation in responses. Similarly, statements with 70% or more disagreement (strongly disagree or disagree) were considered to have met consensus for exclusion. Statements with 30% or less agreement in the first round were defined as "unlikely to reach consensus" and excluded from the second round. Therefore, all statements achieving agreement or disagreement of 70% or more and those with 30% or less agreement were not re-rated in the second round. Descriptive statistics were used to summarise overall scores. All free-text responses were provided in English, evaluated by the DSMC and, where applicable, used to make amendments or clarifications for Delphi statements in the second round.

For more on **Rev** see https://www.rev.com/

For more on **Qualtrics** see https://www.qualtrics.com/uk/

## Results

### Core Expert Panel interviews

A total of 22 concepts or themes emerged from the interviews with Core Expert Panel members and centred broadly on the range of possible HRCT phenotypes, and the relationships between specific HRCT features and lung function tests, clinical features, and outcomes in sarcoidosis (appendix p 7). Ten concepts based on HRCT appearances were described in more than 90% of thematic interviews with Core Expert Panel members. Among these concepts, there was unanimous agreement that there are distinct HRCT phenotypes in sarcoidosis, but there were diverse views on what constitutes a distinct HRCT phenotype. For instance, although there was consensus that a peri-lymphatic nodular pattern

represents a distinct HRCT phenotype, the suggestion of an HRCT pattern mimicking usual interstitial pneumonia was recognised by only a few Core Expert Panel members. After review of the concepts and themes by the DSMC, 34 statements were created—for example, the theme "progressive massive fibrosis (PMF) phenotype, even with airway distortion, can respond dramatically to treatment" gave rise to the following Delphi statement: "An HRCT pattern comprising large bronchocentric masses (ie, PMF lookalike) can regress with treatment". See appendix (pp 8–9) for the 34 statements written in full, as presented to all study participants.

### Demographics and characteristics of Delphi participants

Between March 23, 2021, and April 13, 2021, 146 of 174 individuals (84%; 48 thoracic radiologists, 98 chest physicians; mean duration in practice 21 years [SD 10 years]) who originally accepted the invitations to participate completed the first round of the Delphi process (table 1). There was diverse geographical representation, but most participants were practising in the USA (25%) and the UK or mainland Europe (France 10%, Italy 9%, UK 8%, the Netherlands 7%, and Germany 5%; appendix p 10). At registration, 145 of 146 participants (99%) confirmed expertise in ILD, with 130 of 146 participants (89%) also indicating a specialist interest in sarcoidosis. The majority of radiologists (44 of 48 [92%]) indicated that more than 50% of their reporting time was spent reviewing thoracic imaging studies. The number of patients with sarcoidosis assessed annually by chest physicians was distributed evenly across annual number categories (<50 patients through to >250 patients; table 1). The second round of the Delphi process took place between May 17, 2021, and June 17, 2021, and 144 of the original 146 participants (99%) completed the survey. See figure 1 for an overview of the study participants and consensus development process.

| | Mean (SD) or n (%) |
|---|---|
| Age, years | 53 (SD 10) |
| Sex | |
| Male | 82 (56%) |
| Female | 62 (42%) |
| Prefer not to say | 2 (1%) |
| Geographical region | |
| Africa | 2 (1%) |
| Asia | 18 (12%) |
| UK and mainland Europe | 76 (52%) |
| USA, Mexico, and Canada | 39 (27%) |
| South America | 7 (5%) |
| Oceania | 4 (3%) |
| Years in senior practice | 21 (SD 10) |
| Specialty | |
| Chest physician | 98 (67%) |
| Thoracic radiologist | 48 (33%) |
| Special interest | |
| Interstitial lung disease | 145 (99%) |
| Sarcoidosis | 130 (89%) |
| Chest physicians: approximate numbers of sarcoid patients evaluated per year | |
| <50 | 23 (23%) |
| 50–100 | 24 (24%) |
| 101–250 | 27 (28%) |
| >250 | 24 (24%) |
| Radiologists: proportion of time devoted to thoracic imaging | |
| <25% | 1 (2%) |
| 25–50% | 3 (6%) |
| 51–75% | 14 (29%) |
| >75% | 30 (62%) |

146 participants from 28 countries participated in the Delphi exercise. Not all percentages add up to 100% owing to rounding.

***Table 1:*** **Demographic and other characteristics of participants in the Delphi consensus process**

### Delphi surveys

*Overall responses and modifications to statements after the first round*

In the first round of the Delphi process, 34 statements were rated by 146 participants. A summary of responses to all statements in the first round is provided in figure 2 (appendix pp 11–12). On completion of the first round, 13 of 34 statements (38%) reached the 70% threshold for consensus agreement, with no statements meeting the criteria for consensus disagreement. Three statements achieved less than 30% agreement, thereby meeting the "unlikely to reach consensus" criteria, and were removed for the purposes of the second round. A single statement that did not meet either of these criteria ("'Soft' intra-thoracic nodal calcification with hepatic and splenic calcified granulomas favours histoplasmosis over sarcoidosis") was removed following review by the DSMC because it was considered to be outside the scope of the study. Therefore, 17 statements from the first round were taken forward for re-rating in the second round.

In addition to responses to specific Delphi statements, participants also submitted 619 free-text comments in the first round; all comments were reviewed by the DSMC to identify areas of uncertainty requiring clarification in the second round. Two key areas of uncertainty emerged from the free-text comments in the first round. First, there was a perception among some participants that the

***Figure 2:*** **Summary of responses to statements in Delphi rounds 1 and 2**
All statements that were presented in round 2 were preceded by the text, "In patients with a confirmed diagnosis of sarcoidosis", and some statements that were presented in round 2 included modifications for clarity (see appendix pp 8–9 for full statements, as presented to study participants, and appendix p 13 for all modifications to statements presented in round 2). HRCT=high-resolution CT. NA=not applicable. *Statement 27 was considered to be outside the scope of the study by the Delphi Study Management Committee and excluded after the first round. †Statement 35 was added in the second round to explore a clinically important question that was not addressed in the first round.

Delphi statements reaching consensus agreement threshold (≥70% agreement) Delphi statements not reaching consensus agreement threshold (>30% to <70% agreement or <70% disagreement)
Delphi statements meeting criteria for exclusion (≥70% disagreement or ≤30% agreement)

| | Outcomes of Delphi surveys (%) | |
|---|---|---|
| **Delphi statement** | **Round 1** | **Round 2** |
| 1) HRCT should be performed at baseline in patients with sarcoidosis and evidence of pulmonary interstitial involvement | Consensus agreement (95%) | NA |
| 2) There are distinct HRCT phenotypes in sarcoidosis | Consensus agreement (97%) | NA |
| 3) HRCT features can be categorised as fibrotic and non-fibrotic | Consensus agreement (83%) | NA |
| 4) Nodules alone or a predominance of nodules are almost always non-fibrotic | Consensus agreement (82%) | NA |
| 5) A predominant ground-glass opacification pattern is almost always non-fibrotic (in the absence of ancillary HRCT features of fibrosis) | No consensus (54%) | Consensus agreement (80%) |
| 6) A predominant consolidation pattern is almost always non-fibrotic | No consensus (34%) | No consensus (33%) |
| 7) A predominant mosaic attenuation pattern is almost always non-fibrotic | No consensus (42%) | No consensus (56%) |
| 8) Nodules as the predominant or sole abnormality are a distinct HRCT pattern in sarcoidosis | Consensus agreement (82%) | NA |
| 9) Multiple peri-bronchovascular, peri-fissural, or subpleural micronodules are a distinct pattern | Consensus agreement (97%) | NA |
| 10) Multiple randomly distributed micronodules are a distinct pattern | No consensus (57%) | No consensus (66%) |
| 11) Multiple larger peri-bronchovascular nodules are a distinct pattern | Consensus agreement (78%) | NA |
| 12) Scattered larger nodules are a distinct pattern (nodular phenotype) | No consensus (47%) | Consensus agreement (73%) |
| 13) Scattered larger cavitating nodules are a distinct pattern | Exclude (18%) | NA |
| 14) Ground-glass opacification as the predominant or sole abnormality is a distinct pattern | No consensus (45%) | No consensus (60%) |
| 15) Consolidation as the predominant or sole abnormality is a distinct pattern | No consensus (62%) | Consensus agreement (92%) |
| 16) Mosaic attenuation as the predominant or sole abnormality is a distinct pattern | Exclude (29%) | NA |
| 17) Reticulation on HRCT almost always represents fibrosis | No consensus (59%) | Consensus agreement (80%) |
| 18) Interlobular septal thickening on HRCT represents fibrosis | Exclude (23%) | NA |
| 19) Large bronchocentric masses with or without cystic or bullous destruction almost always represent fibrosis | No consensus (62%) | Consensus agreement (83%) |
| 20) Bronchocentric reticulation with or without dense parenchymal opacification, without cavitation, is a distinct pattern | Consensus agreement (81%) | NA |
| 21) Bronchocentric reticulation and dense parenchymal opacification, with cavitation, is a distinct pattern | Consensus agreement (78%) | NA |
| 22) Large bronchocentric masses (ie, progressive massive fibrosis lookalike) are a distinct pattern | Consensus agreement (79%) | NA |
| 23) Predominant interlobular septal thickening is a distinct pattern | No consensus (43%) | No consensus (69%) |
| 24) Mid-zone or lower zone-predominant subpleural reticulation with or without honeycombing (ie, usual interstitial pneumonia or non-specific interstitial pneumonia lookalike) is a distinct pattern | No consensus (39%) | No consensus (40%) |
| 25) Pleuroparenchymal fibroelastosis lookalike is a distinct pattern | No consensus (46%) | No consensus (69%) |
| 26) "Soft" intra-thoracic (mediastinal or hilar) nodal calcification occurs in sarcoidosis | Consensus agreement (96%) | NA |
| 27) "Soft" intra-thoracic nodal calcification with hepatic and splenic calcified granulomas favours histoplasmosis over sarcoidosis* | Exclude (45%) | NA |
| 28) Specific HRCT appearances correspond to specific lung function profiles | No consensus (60%) | Consensus agreement (80%) |
| 29) A predominant reticular pattern on HRCT is associated with a restrictive lung function defect | Consensus agreement (71%) | NA |
| 30) A bronchocentric pattern of fibrosis is associated with an obstructive lung function defect | No consensus (54%) | Consensus agreement (72%) |
| 31) A predominant nodular pattern on HRCT is associated with bronchoalveolar lavage lymphocytosis | No consensus (60%) | No consensus (69%) |
| 32) Bronchocentric reticulation with or without dense parenchymal opacification, with cavitation, predicts a poor response to treatment | Consensus agreement (82%) | NA |
| 33) A minority of patients with sarcoidosis and a progressive massive fibrosis lookalike pattern on HRCT can demonstrate partial or complete regression with treatment | No consensus (53%) | Consensus agreement (72%) |
| 34) Lobar volume loss (particularly the upper lobes) is associated with a poor outcome | No consensus (53%) | Consensus agreement (71%) |
| 35) HRCT findings strongly indicative of fibrotic disease are associated with bronchoalveolar lavage neutrophilia† | NA | No consensus (34%) |

Delphi statements were referring to the diagnostic utility of specified patterns or phenotypes on HRCT. Second, there was misinterpretation among some participants that the purpose of the study was to comment on whether the provided volumetric sample HRCT datasets were representative of specific Delphi statements. Issues raised in the free-text comments were resolved before the commencement of the second round through review by the DSMC. Other areas of uncertainty highlighted in the free-text comments were clarified by email, in the instructions provided for the second round, or both.

Finally, a single new statement, "HRCT findings strongly indicative of fibrotic disease are associated with bronchoalveolar lavage neutrophilia", was added as a variant of an existing statement to address a topic that the DSMC felt was important to explore. Thus, in the second round of the Delphi process, 144 participants were presented with 18 statements (figure 2; appendix p 13), which were evaluated in the same manner as in the first round. Importantly, in the second round, participants were provided with feedback for all statements that had been modified after the first round. On completion of the second round, there was consensus agreement on a further nine statements; thus, consensus agreement was reached for 22 of the 35 statements (63%) presented over both rounds. No statements met the criteria for consensus disagreement or "unlikely to reach consensus".

### *Role of HRCT and consensus on fibrotic and non-fibrotic HRCT patterns*

There was a high level of agreement among participants for the statement that "HRCT should be performed at baseline in patients with sarcoidosis and evidence of pulmonary interstitial involvement" (95% agreement) and that "There are distinct HRCT phenotypes in sarcoidosis" (97% agreement).

The following Delphi statements regarding the possible pathological meaning of HRCT patterns also achieved consensus agreement: (1) "HRCT features can be categorised as fibrotic and non-fibrotic" (83% agreement); (2) "Nodules alone or a predominance of nodules are almost always non-fibrotic" (82% agreement); and, after clarification or feedback in the second round (including the addition of the text, "In patients with a confirmed diagnosis of sarcoidosis", which preceded all second-round statements), (3) "Reticulation on HRCT almost always represents fibrosis" (80% agreement); (4) "Large bronchocentric masses with or without cystic or bullous destruction almost always represent fibrosis" (83% agreement); and (5) "A predominant ground-glass opacification pattern is almost always non-fibrotic (in the absence of ancillary HRCT features of fibrosis)" (80% agreement). By contrast, the following Delphi statements did not reach consensus agreement: (1) "A predominant consolidation pattern is almost always non-fibrotic" (33% agreement); and (2) "A predominant mosaic attenuation pattern is almost always non-fibrotic" (56% agreement).

| | Consensus agreement |
|---|---|
| **Non-fibrotic subtypes** | |
| Multiple peri-bronchovascular, peri-fissural, or subpleural micronodules (figure 3A)* | 97% |
| Multiple larger peri-bronchovascular nodules (figure 3B)* | 78% |
| Scattered larger nodules (figure 3C)† | 73% |
| Consolidation as the predominant or sole abnormality (figure 3D)† | 92% |
| **Likely to be fibrotic subtypes** | |
| Bronchocentric reticulation with or without dense parenchymal opacification, without cavitation (figure 4A, 4B)* | 81% |
| Bronchocentric reticulation and dense parenchymal opacification, with cavitation (figure 4C)* | 78% |
| Large bronchocentric masses (ie, PMF lookalike; figure 4D)* | 79% |

The seven principal phenotypes are broadly broken down into non-fibrotic and likely to be fibrotic subtypes. PMF=progressive massive fibrosis. *Delphi statements that reached the consensus agreement threshold in round 1. †Delphi statements that reached the consensus agreement threshold in round 2, after clarifications or feedback.

*Table 2:* **High-resolution CT phenotypes that reached consensus agreement during the Delphi process**

### *Distinct (recognisable) HRCT phenotypes*

On completion of the second round of the Delphi process, there was consensus agreement on seven HRCT phenotypes, which were broadly divided into the non-fibrotic and likely to be fibrotic subtypes (table 2, figures 3, 4). Of the seven agreed phenotypes, five reached consensus in the first round (consensus agreement 78–97%). Of the non-fibrotic HRCT phenotypes, the phenotypic pattern of "Multiple peri-bronchovascular, peri-fissural, or subpleural micronodules" had the highest level of expert agreement (97%). Only two phenotypes met the criteria for "unlikely to reach consensus".

### *Relationships between HRCT phenotypes and lung function or outcome*

There was agreement on six statements that specific HRCT appearances correspond to specific lung function profiles, outcome measures, or responses to treatment: in particular, specific HRCT appearances were considered to correspond to specific lung function profiles by 80% of experts, with 71% agreeing that "A predominant reticular pattern on HRCT is associated with a restrictive lung function defect" and 72% agreeing that "A bronchocentric pattern of fibrosis is associated with an obstructive lung function defect". In terms of relationship to outcome, most participants (72%) agreed that "A minority of patients with sarcoidosis and a PMF lookalike pattern on HRCT can demonstrate partial or complete regression with treatment". Lobar volume loss was considered, by consensus (71%), to be a marker of poor outcome. There was also 82% agreement on the statement that "Bronchocentric reticulation with or without dense parenchymal opacification, with cavitation, predicts a poor response to treatment".

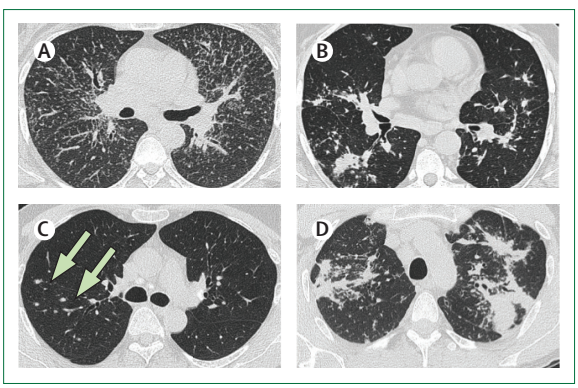


*Figure 3:* **Sample HRCT images from four patients showing four phenotypes, considered to be non-fibrotic, that reached consensus in the Delphi process**
(A) HRCT image just below the carina showing innumerable peri-bronchovascular, peri-fissural, and subpleural micronodules. (B) HRCT image through the mid-zone of the chest showing multiple larger peri-bronchovascular nodules; some of the larger nodules have smaller surrounding micronodules (the galaxy sign). (C) HRCT image at the level of the carina showing scattered larger nodules (arrows), which appear to be unrelated to the bronchovascular structures. (D) HRCT section at the level of the aortic arch showing a pattern of predominant consolidation. HRCT=high-resolution CT.

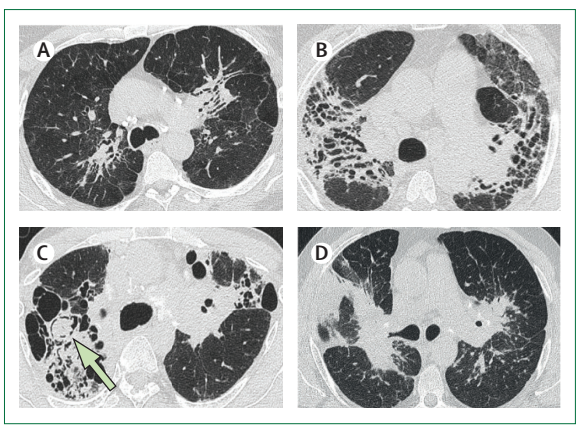


*Figure 4:* **Sample HRCT images from four patients showing three phenotypes, considered likely to be fibrotic, that reached consensus in the Delphi process**
(A) HRCT image at the level of the carina with bilateral bronchocentric reticulation; there is also a pattern of loose reticulation in both lungs. (B) HRCT image through the upper lobes showing more extensive, symmetrical bronchocentric reticulation. (C) HRCT image just above the carina demonstrating upper lobe fibrocavitary disease; there is a mycetoma in one of the right upper lobe cavities (arrow). (D) HRCT image just below the carina showing dense, bilateral bronchocentric masses giving an appearance of progressive massive fibrosis; there are a few scattered micronodules in the left lung but this is not the dominant abnormality. HRCT=high-resolution CT.

## Discussion

The principal aim of this study—the first and largest of its type, we believe—was to evaluate consensus on recognisable HRCT phenotypes in sarcoidosis using a modified Delphi process. The study was undertaken as a prelude to the eventual formulation of a formal CT classification, as opposed to the historical approach in which a wide range of morphologies are lumped under the generic label of sarcoidosis. This historical approach runs counter to that used for other diffuse diseases in which splitting, variably based on pathological features, CT appearances, patterns of functional impairment, and disease behaviour or outcome, is the norm.[13–15] A CT phenotype classification has the potential to ground future research initiatives, providing a morphological framework for research and a substitute for histological evaluation. In principle, this might apply to further studies on the diagnostic accuracy of individual CT phenotypes, patterns of pulmonary function impairment, major separations in outcome, and relationships with genetic predilection and specific sarcoidosis triggers.

An important clinical message arising from the Delphi exercise was the strong agreement that HRCT should be performed at baseline in patients with evidence of pulmonary involvement. The strength of consensus (95%) was surprising: there is little doubt that CT is more sensitive than plain chest radiography[16,17] but, to date, there has been no consensus or guidance on the role of HRCT in routine assessment. In the original 1999 American Thoracic Society–European Respiratory Society–World Association of Sarcoidosis and other Granulomatous Disorders Consensus Statement on Sarcoidosis,[18] chest radiography was regarded as the mainstay of radiological diagnosis, with CT being reserved for the assessment of atypical or unclear findings on chest radiography and the detection of complications. The more recent British Thoracic Society clinical statement also suggests that the use of CT should be based on conclusions reached through evaluation with chest radiography.[19] The fact that a large majority of multinational experts in the current study supported the routine use of HRCT in evaluating the lungs at baseline is a potentially important consideration for future guideline development, although the important issues of cost, availability of (and accessibility to) HRCT worldwide, and the added radiation burden must not be ignored.

In the current study, participants agreed not only that there are recognisable HRCT phenotypes in sarcoidosis, but also that HRCT abnormalities can be categorised broadly as fibrotic or non-fibrotic. Among the HRCT phenotypic subtypes recognised by Delphi participants, there was widespread agreement about (non-fibrotic) nodular patterns and, in particular, the micronodular forms: in the first Delphi round, 97% of participants either agreed or strongly agreed that multiple bronchocentric, peri-fissural, or subpleural micronodules comprise a distinct HRCT pattern in sarcoidosis. This is not surprising because variants of a nodular pattern have long been regarded as classic signs on CT in sarcoidosis.[20–24] The distinction between nodular patterns, based on size, is interesting, with macronodules presumably reflecting coalescence of granulomata and supposedly signifying more extensive disease.[25] Taken further, and in contrast to micronodular CT patterns, Aleksonienė and co-workers reported an association between the extent of macronodules on CT and lung function decline.[24] The view that individual CT patterns

might be linked to particular patterns of functional impairment is now supported by this international consensus study.

Three other morphological phenotypes—namely, bronchocentric reticulation with or without dense parenchymal opacification but no cavitation, bronchocentric reticulation and dense parenchymal opacification with cavitation, and a PMF-like pattern—which, broadly speaking, we consider to be fibrotic, were identified through the Delphi process. In a previous small study comprising 80 consecutive patients with stage 4 disease on chest radiography, Abehsera and colleagues attempted to phenotype the different forms of fibrosis in sarcoidosis.[2] In just under half of cases, there was predominant central bronchial distortion on CT; review of the CT images in the report suggests that this pattern corresponds to the pattern of bronchocentric reticulation without cavitation identified in our Delphi process. It is noteworthy that there was disagreement between the two observers in the study by Abehsera and colleagues in distinguishing between the bronchial distortion and linear patterns on one of the CT images.[2] A final, but important, critique of the earlier paper concerns the pattern of peripheral honeycombing in sarcoidosis. A pattern mimicking usual interstitial pneumonia has been reported in sarcoidosis.[6,26,27] Furthermore, in the study by Abehsera and colleagues, honeycombing, not necessarily in a classic usual interstitial pneumonia–idiopathic pulmonary fibrosis distribution, was reported in nearly a third of patients.[2] In the current Delphi process, there was no consensus either for or against usual interstitial pneumonia as a distinct HRCT phenotype in patients with a confirmed diagnosis of sarcoidosis, highlighting the need to determine whether usual interstitial pneumonia represents a distinct phenotype or a concurrent pathological process in patients with sarcoidosis.

A number of morphological phenotypes that did not achieve consensus in the first Delphi round did so in the second round after clarification. This is an obvious strength of the Delphi process, which allows clarifications between rounds. Indeed, a pattern of consolidation in patients with proven sarcoidosis eventually emerged as one of the final seven recognised HRCT sarcoid phenotypes. Against this, a number of proposed HRCT phenotypes did not achieve consensus. Indeed, the presence of scattered large cavitating nodules, a mosaic attenuation pattern, and interlobular septal thickening all fell below the a priori threshold for consensus agreement in the first round of the Delphi process. There is a traditional view that the CT manifestations of sarcoidosis are highly varied. Even so, cavitating nodules (to be differentiated from the fibrocavitary disease that is apparent in some patients) must be considered among the rare, if not rarest, of CT manifestations. The current international consensus is in line with this conclusion. By contrast with cavitating nodules, the finding that a mosaic attenuation pattern—reflecting obstructive small airways disease—did not reach consensus was more surprising. Involvement of airways in sarcoidosis is well documented:[1,28–30] Gleeson and colleagues found evidence of air trapping on expiratory CT in three patients with sarcoidosis.[28] Similarly, but in a larger CT study, areas of decreased attenuation at end-expiration were present in 40 of 45 cases (89%) and the extent of decreased attenuation was independently linked to airflow limitation.[1] The reason why this pattern of abnormality on CT (and that of interlobular septal thickening) did not reach consensus is not entirely clear. One explanation might be that such patterns are often seen in combination with other signs of sarcoidosis (eg, nodules, reticulation) and, accordingly, might not be regarded as typical of sarcoidosis.

As part of the Delphi exercise, we took the opportunity to explore views on possible relationships between HRCT appearances and the following areas of uncertainty, as endorsements for future research: (1) pathological meaning; (2) patterns of functional impairment; (3) treatment implications; and (4) prognosis. For example, there was agreement that two HRCT patterns were generally indicative of established fibrosis—namely, a reticular pattern and large bronchocentric masses. However, CT features not used in phenotype designation, especially traction bronchiectasis and distortion, need to be explored further. There was consensus agreement that in a minority of patients, a PMF-like pattern might partially or completely regress with treatment. Historically, this pattern of fibrosis has most often been linked to occupational exposures and, more often than not, signifies end-stage disease.[31,32] However, on the basis of participant experience, a PMF-like appearance on HRCT might sometimes represent, at least in part, intense but reversible granulomatous aggregation.

A significant limitation of this study is that despite the multinational nature of the participant group, the higher representation of European and North American countries might have created bias, given that sarcoidosis manifestations might vary between countries and ethnicities. It is also important to emphasise that we do not consider the Delphi process to be synonymous with or a surrogate for high-quality research—the clinical and pathogenetic significance of phenotypic separation requires research that goes far beyond the scope of consensus agreement. However, research into the possible designation of separate diseases has, in the past, been grounded on histological distinctions that cannot be made effectively in pulmonary sarcoidosis. In this Position Paper, the Delphi consensus that HRCT phenotypic separations can be made is an essential first step towards a formal CT classification of pulmonary sarcoidosis.

Nevertheless, further CT studies, which we believe to be rapidly achievable, are required to inform the development of a formal classification (panel). Observer variability needs to be evaluated, recognising that this might be

*Panel:* **Proposed avenues for future research in pulmonary sarcoidosis**

**Considerations for studies in the formulation of a CT classification**

- Observer variability in phenotype designation
- Prevalence of individual phenotypes (to include geographical variation)
- Further evaluation of patients not satisfying phenotypic criteria
- Possible evolution of phenotypes

**Exploration of CT phenotypes in the context of the following areas of investigation**

- Robust diagnostic criteria
- Patterns of lung function impairment
- Disease behaviour (to include serial lung function change and mortality)
- Genetic profiles
- Triggers of sarcoidosis (to include combined genetic or trigger predilections)
- Key pathogenetic pathways

hampered by the novelty of a classification, and phenotype definition might need to be modified to deal with sources of inter-observer variability. The prevalence of individual phenotypes needs to be explored with important sub-questions. The proportion of patients in whom phenotypic separation cannot be achieved, according to the current consensus, needs to be defined, with possible refinements in this subgroup, perhaps based on cluster analyses of HRCT features. The possibility that the CT phenotype in an individual patient might evolve from one prevailing phenotype to another must be formally evaluated, although accumulated experience suggests that this is highly infrequent. Above all, a formal CT classification based on obvious morphological differences should not integrate incomplete existing data suggesting relationships between phenotypes and outcomes or diagnostic utility. Rather, these questions should be explored rigorously once a classification has been proposed (an initiative that is now underway). Conclusions reached in subsequent studies of pathogenesis and clinical utility should, in turn, be used to consider modification of a proposed classification. Some of the conclusions reached in this Delphi exercise could be used to shape plausible future research. For example, Delphi consensus on categorisation into fibrotic and non-fibrotic phenotypes adds potential value to phenotype separation but does not, in itself, contribute to phenotype separation. This question needs to be explored after a provisional classification has been developed with consideration of CT fibrotic features that occur in more than one phenotype, including traction bronchiectasis and distortion.

In conclusion, the international consensus on discrete HRCT phenotypes in pulmonary sarcoidosis presented in this Position Paper supports the development of a CT classification framework for pulmonary sarcoidosis and provides justification for the use of such a classification for future studies of subgroup differences in genetic predilection, initiating pathways, mechanisms of progression, response to treatment, and patterns of lung function impairment, with implications for diagnostic algorithms and assessment of outcomes. In the absence of robust categorical histological separations between subgroups in pulmonary sarcoidosis, CT morphological distinctions could have a central role in future research.

**Contributors**

SRD, NSi, KAJ, and AUW formed the Delphi Study Management Committee. KAJ, DAC, AD, DAL, DM, HN, NSv, PS, RPB, SP, and SLFW formed the Core Expert Panel. SRD, NSi, and AUW were responsible for study conceptualisation, methods, investigation, study supervision, project administration, survey conduct, data curation, formal analysis, writing of the original draft, and reviewing and editing of the manuscript. KAJ was involved in the methods, survey conduct, formal analysis, and writing of the original draft. PMG, DAC, AD, DAL, DM, ER, HN, NSv, PS, RPB, RY, SP, SLFW, and VK were involved in the investigation and reviewing and editing of the manuscript. SRD, NSi, and AUW accessed and verified the underlying data reported in the manuscript. All authors had full access to all the data in the study and accept responsibility to submit for publication.

**Declaration of interests**

SRD has received consulting fees for participation as an external expert steering committee member for a phase 3b/4 trial of trastuzumab deruxtecan in stage IV breast cancer from AstraZeneca and honoraria for travel expenses and for tutoring on radiology masterclasses in interstitial lung disease (ILD) from Boehringer Ingelheim; he is a co-founder and clinical director of, and holds shares in, DMC Radiology Reporting (an outsourcing, teleradiology company with no research or commercial interest in sarcoidosis). NSi has received honoraria for lectures from the World Association of Sarcoidosis and other Granulomatous Disorders (WASOG), Associazione Polo Italia-Cina, and Boehringer Ingelheim. KAJ has received grants from Three Lakes Foundation, the Chest Foundation, the University of Calgary Cumming School of Medicine, and the University Hospital Foundation (affiliated with the University of Alberta), consulting fees from Boehringer Ingelheim, Hoffman-La Roche, Pliant Therapeutics, Three Lakes Foundation, and Thyron SAB, and honoraria for lectures from Boehringer Ingelheim and Hoffman-La Roche; she has participated on the data safety monitoring board (DSMB) for the Ambulatory Oxygen for Treatment of Exertional Hypoxaemia in Pulmonary Fibrosis (PFOX) trial (no payment received). PMG has received grants from Boehringer Ingelheim, speaker's fees from Boehringer Ingelheim, Roche, Teva, Cipla, and Brainomix, and travel support from Boehringer Ingelheim and Roche; he is a medical director of, and holds stock options in, Brainomix (a company that develops artificial intelligence-powered imaging technologies unrelated to the submitted work). DAC has received grants from Boehringer Ingelheim, the Ann Theodore Foundation, the Foundation for Sarcoidosis Research, and aTyr, consulting fees from Kinevant and CSL Behring, and travel support from Roche. AD has received consulting fees from Boehringer Ingelheim, Roche, Brainomix, and Vicore; he is a medical director of, and holds stock options in, Brainomix. DAL has received consulting fees from Calyx and has participated on the advisory board for Boehringer Ingelheim. ER has received grants from Boehringer Ingelheim, honoraria for lectures from Boehringer Ingelheim and Chiesi, and travel support from Boehringer Ingelheim; she has participated on advisory boards for Boehringer Ingelheim and Roche. PS has received grants from PPM Services, Boehringer Ingelheim, and Roche, consulting fees from Novartis, Behring, PPM Services, Pieris, and GlycoCore, honoraria for lectures from Chiesi, Boehringer Ingelheim, and Menarini, support for attending meetings from PPM Services and Boehringer Ingelheim, and fees for participation on a DSMB or advisory board from Galapagos, Pieris, Boehringer

Ingelheim, and Novartis, all outside of the submitted work. RPB has received grants from aTyr, Mallinckroft, Bellephron, Genentech, Actelion, and the Foundation for Sarcoidosis Research, consulting fees from aTyr, Kinevent, Bellephron, and the Millikin Center, and speaker's fees for lectures on sarcoidosis and other ILDs from Boehringer Ingelheim, Mallinckrodt, and United Therapeutics. SLFW has received grants from Boehringer Ingelheim and Galapagos, consulting fees from Boehringer Ingelheim, Roche, Galapagos, the Open Source Imaging Consortium, Puretech, Pliant, Oncorendi Therapeutics, and FLUIDDA, and honoraria for lectures and for developing educational material from Boehringer Ingelheim; he has participated on advisory boards for Boehringer Ingelheim and Roche. VK has received speaker's fees from Boehringer Ingelheim and Novartis. AUW has received consulting fees from Roche and Veracyte, and honoraria for lectures and presentations from Boehringer Ingelheim, Roche, and Veracyte; he is the president of the WASOG. All other authors declare no competing interests.

**References**

1 Hansell DM, Milne DG, Wilsher ML, Wells AU. Pulmonary sarcoidosis: morphologic associations of airflow obstruction at thin-section CT. *Radiology* 1998; **209:** 697–704.

2 Abehsera M, Valeyre D, Grenier P, Jaillet H, Battesti JP, Brauner MW. Sarcoidosis with pulmonary fibrosis: CT patterns and correlation with pulmonary function. *AJR Am J Roentgenol* 2000; **174:** 1751–57.

3 Nunes H, Uzunhan Y, Gille T, Lamberto C, Valeyre D, Brillet PY. Imaging of sarcoidosis of the airways and lung parenchyma and correlation with lung function. *Eur Respir J* 2012; **40:** 750–65.

4 Kouranos V, Ward S, Kokosi MA, et al. Mixed ventilatory defects in pulmonary sarcoidosis: prevalence and clinical features. *Chest* 2020; **158:** 2007–14.

5 Bergin CJ, Bell DY, Coblentz CL, et al. Sarcoidosis: correlation of pulmonary parenchymal pattern at CT with results of pulmonary function tests. *Radiology* 1989; **171:** 619–24.

6 Padley SP, Padhani AR, Nicholson A, Hansell DM. Pulmonary sarcoidosis mimicking cryptogenic fibrosing alveolitis on CT. *Clin Radiol* 1996; **51:** 807–10.

7 Scadding JG. Prognosis of intrathoracic sarcoidosis in England. A review of 136 cases after five years' observation. *BMJ* 1961; **2:** 1165–72.

8 Diamond IR, Grant RC, Feldman BM, et al. Defining consensus: a systematic review recommends methodologic criteria for reporting of Delphi studies. *J Clin Epidemiol* 2014; **67:** 401–09.

9 Graneheim UH, Lundman B. Qualitative content analysis in nursing research: concepts, procedures and measures to achieve trustworthiness. *Nurse Educ Today* 2004; **24:** 105–12.

10 Jünger S, Payne SA, Brine J, Radbruch L, Brearley SG. Guidance on Conducting and REporting DElphi Studies (CREDES) in palliative care: recommendations based on a methodological systematic review. *Palliat Med* 2017; **31:** 684–706.

11 Sinha IP, Smyth RL, Williamson PR. Using the Delphi technique to determine which outcomes to measure in clinical trials: recommendations for the future based on a systematic review of existing studies. *PLoS Med* 2011; **8:** e1000393.

12 Diamond IR, Grant RC, Feldman BM, et al. Defining consensus: a systematic review recommends methodologic criteria for reporting of Delphi studies. *J Clin Epidemiol* 2014; **67:** 401–09.

13 Liebow AA. Definition and classification of interstitial pneumonias in human pathology. *Progr Respir Res* 1975; **8:** 1–31.

14 Raghu G, Collard HR, Egan JJ, et al. An official ATS/ERS/JRS/ALAT statement: idiopathic pulmonary fibrosis: evidence-based guidelines for diagnosis and management. *Am J Respir Crit Care Med* 2011; **183:** 788–824.

15 Travis WD, Costabel U, Hansell DM, et al. An official American Thoracic Society/European Respiratory Society statement: update of the international multidisciplinary classification of the idiopathic interstitial pneumonias. *Am J Respir Crit Care Med* 2013; **188:** 733–48.

16 Drent M, De Vries J, Lenters M, et al. Sarcoidosis: assessment of disease severity using HRCT. *Eur Radiol* 2003; **13:** 2462–71.

17 Oberstein A, von Zitzewitz H, Schweden F, Müller-Quernheim J. Non invasive evaluation of the inflammatory activity in sarcoidosis with high-resolution computed tomography. *Sarcoidosis Vasc Diffuse Lung Dis* 1997; **14:** 65–72.

18 Hunninghake GW, Costabel U, Ando M, et al. Statement on sarcoidosis. *Am J Respir Crit Care Med* 1999; **160:** 736–55.

19 Thillai M, Atkins CP, Crawshaw A, et al. BTS Clinical Statement on pulmonary sarcoidosis. *Thorax* 2021; **76:** 4–20.

20 Ors F, Gumus S, Aydogan M, Sari S, Verim S, Deniz O. HRCT findings of pulmonary sarcoidosis; relation to pulmonary function tests. *Multidiscip Respir Med* 2013; **8:** 8.

21 Benamore R, Kendrick YR, Repapi E, et al. CTAS: a CT score to quantify disease activity in pulmonary sarcoidosis. *Thorax* 2016; **71:** 1161–63.

22 Lynch DA, Webb WR, Gamsu G, et al. Computed tomography in pulmonary sarcoidosis. *J Comput Assist Tomogr* 1989; **13:** 405–10.

23 Leung AN, Brauner MW, Caillat-Vigneron N, Valeyre D, Grenier P. Sarcoidosis activity: correlation of HRCT findings with those of 67Ga scanning, bronchoalveolar lavage, and serum angiotensin-converting enzyme assay. *J Comput Assist Tomogr* 1998; **22:** 229–34.

24 Aleksonienė R, Zeleckienė I, Matačiūnas M, et al. Relationship between radiologic patterns, pulmonary function values and bronchoalveolar lavage fluid cells in newly diagnosed sarcoidosis. *J Thorac Dis* 2017; **9:** 88–95.

25 Müller NL, Kullnig P, Miller RR. The CT findings of pulmonary sarcoidosis: analysis of 25 patients. *AJR Am J Roentgenol* 1989; **152:** 1179–82.

26 Shigemitsu H, Oblad JM, Sharma OP, Koss MN. Chronic interstitial pneumonitis in end-stage sarcoidosis. *Eur Respir J* 2010; **35:** 695–97.

27 Tachibana K, Arai T, Kagawa T, et al. A case of combined sarcoidosis and usual interstitial pneumonia. *Intern Med* 2012; **51:** 1893–97.

28 Gleeson FV, Traill ZC, Hansell DM. Evidence of expiratory CT scans of small-airway obstruction in sarcoidosis. *AJR Am J Roentgenol* 1996; **166:** 1052–54.

29 Sharma OP, Johnson R. Airway obstruction in sarcoidosis. A study of 123 nonsmoking black American patients with sarcoidosis. *Chest* 1988; **94:** 343–46.

30 Davies CWH, Tasker AD, Padley SPG, Davies RJO, Gleeson FV. Air trapping in sarcoidosis on computed tomography: correlation with lung function. *Clin Radiol* 2000; **55:** 217–21.

31 Blackley DJ, Reynolds LE, Short C, et al. Progressive massive fibrosis in coal miners from 3 clinics in Virginia. *JAMA* 2018; **319:** 500–01.

32 Centers for Disease Control and Prevention (CDC). Pneumoconiosis and advanced occupational lung disease among surface coal miners—16 states, 2010–2011. *MMWR Morb Mortal Wkly Rep* 2012; **61:** 431–34.

Copyright © 2023 Elsevier Ltd. All rights reserved.